



Mandibular osteonecrosis due to bisphosphonate use

Ahmet Şalvarcı¹, Serdar Altınay²

ABSTRACT

Due to their efficient osteoclastic inhibitor effect in bone metabolism and antiangiogenic activity, bisphosphonates are widely used in many cancer diseases particularly in prostate cancers with bone metastasis, lung cancer, breast cancer and multiple myeloma, as well as in systemic diseases such as osteoporosis, osteopenia, Paget disease and osteogenesis imperfect for the last 13 years. Prostate cancer is a common cancer in males and it is the leading cause of bone metastasis. Mandibular metastasis is rarely encountered during the course of prostate cancer. Mandibular osteonecrosis as well has begun to be observed along with the availability of more efficient and stronger formulations developed following the use of bisphosphonates. Zoledronic acid, which has been used also by our patient, has widely come into practice as a 3rd generation bisphosphonate. Because of prostate cancer and widespread bone metastases, our patient has been receiving zoledronic acid with maximum androgen blockage for 4 years. Tomography of the patient, who has undergone intensive treatment because of submandibular abscess, demonstrated extensive osteonecrosis in the fovea sublingual region of the mandible corpus. In large series, although, mandibular osteonecrosis was widely seen due to bisphosphonate use for the metastases of lung and breast cancers, this rate was between 9.6% and 11% for prostate cancer within the series. Although our patient had no mandibular metastasis before, mandibular necrosis was observed due to long-term bisphosphonate use. We are going to present our patient who had this rare complication with his clinical picture.

Keywords: Bisphosphonate; mandibular; metastatic prostate cancer; osteonecrosis.

Introduction

Prostate cancer is among the most frequently encountered type of cancer in men which most often metastasizes to bone.^[1] The incidence of visceral organ involvement in prostate cancer is 15-20%, while it metastasizes into bones in 80-90% of the cases. In all case-series breast cancers lead the way among cancers involving the facial region, while prostate cancer can metastasize to face in 9-10% of the cases.^[2] Bisphosphonates are widely used in metastatic prostate cancers. Chemically, bisphosphonates are pyrophosphate analogues bound to hydroxyapatite structure of bones. They are resistant to enzymatic fragmentation, and metabolic degradation.^[3,4] Especially bisphosphonates are potent inhibitors of osteoclastic activity. They are eliminated through kidneys without any metabolic degradation. They are poorly absorbed from gastrointestinal tract.^[1-5] Bisphosphonates can be retained in the skeletal system for years without undergoing

any change.^[6] They trigger apoptosis of the cancer cells, prevent their intercellular invasion, and inhibit tumoral invasion.^[6] Besides they have an antiangiogenic properties, and they can activate T-cells.^[7] As a result, bisphosphonates depress bone turnover, and lead to biomechanical insufficiency which may result in formation of rigid, but very fragile skeletal structure. During bisphosphonate use, complications as renal dysfunction, fever, hypocalcemia, esophageal erosion, mandibular, and maxillary osteonecrosis due to suppression of osteoclastic activity can be seen.^[8] Mandibular osteonecrosis has been reported more frequently with new generation potent bisphosphonates.^[8] In the formation of osteonecrosis, long-term use of the drug, advanced age, poor oral hygiene are the most important risk factors, and drug-related osteonecrosis can develop spontaneously.^[9,10] During formation of osteonecrosis bisphosphonates induce obliteration of regional blood vessels, and consequently avascular bone necrosis occurs.^[9]

¹Department of Urology, Konya Hospital, Konya, Turkey

²Department of Pathology, Bağcılar Training and Research Hospital, Istanbul, Turkey

Submitted:
25.09.2013

Accepted:
23.06.2014

Correspondence:
Ahmet Şalvarcı,
Department of Urology, Konya Hospital, Konya, Turkey
Phone: +90 332 350 37 77
E-mail: drsalvarci@hotmail.com

©Copyright 2015 by Turkish Association of Urology

Available online at
www.turkishjournalofurology.com

We will present a patient who developed osteonecrosis, and entered into a phase of spontaneous remission whose mucosal integrity was achieved under conservative treatment without the need for additional treatment.

Case presentation

A 64-year-old patient with lower urinary system complaints was scheduled for transrectal ultrasound-guided 12-quadrant needle core biopsy because of detection of diffuse, and rigid prostate gland palpated 4 years ago during physical examination, and also higher total prostate specific antigen (PSA) (16.3 ng/mL) level. Histopathological diagnosis was Gleason score 4+5 prostate adenocarcinoma. Whole body scanning revealed diffuse bone metastases of the prostate cancer on the right, and left femoral heads, lumbar vertebrae, and left clavicle. The patient was diagnosed as metastatic prostate cancer, and maximal androgen blockade (leuprolide acetate depot 22.5 mg/3 months, and bicalutamide (50 mg/day), and a 3. generation bisphosphonate (zoledronic acid) therapies were initiated. At the 36. month of the treatment, the patient complained of diffusely swollen lower jaw, and oral sores which necessitated consultation to the ENT department, and computed-tomography revealed the presence of diffuse submandibular abscess, and the patient was treated accordingly (Figure 1). The patient consulted to us for urological evaluation 3 months after treatment of his submandibular abscess, and complained of persistence of her lower jaw pain, and difficulty in chewing. We learnt that he was using full arch mandibular, and maxillary dental prostheses for 11 years, and he said that he had been regularly taking care of oral hygiene. On physical examination persistence of incomplete dental closure was observed (Figure 2). Total PSA (0.02 ng/mL), and total testosterone (0.1 ng/mL) levels were measured. Recurrent computed-tomographic examination was reported as osteonecrosis of the sublingual fovea in the mandibular corpus (Figure 3). After approval of the patient was obtained for the publication of information, and photos retrieved, biopsy material was excised from the newly formed mandibular bone tissue with impaired mucosal integrity to determine if this specimen was formed secondary to her disease or related to drug therapy. Histopathological examination revealed patchy areas characterized by empty osteocyte lacunes which made us to establish the diagnosis of necrotic bone (Figure 4). Culture material obtained from exposed mucosa was evaluated as normal oral mucosa. Without the need for additional surgery for exposed mucosa of the osteonecrotic mandible, oral antiseptic solutions, and local agents applied for 3 months achieved spontaneous cure. (Figure 5). Zoledronic acid treatment of the patient who was diagnosed as bisphosphonate-related mandibular osteonecrosis was discontinued, and parathyroid hormone therapy was initiated.

Discussion

In a large series, the development of mandibular, maxillary, and mandibulomaxillary osteonecrosis due to bisphosphonate use has been indicated to occur in 65, 26, and 9% of the cases, respectively. Besides one-third of the patients could be painless, and asymptomatic.^[11,12] Important risk factors for the development of osteonecrosis caused by bisphosphonates include brand of the drug, route, dose, and duration of the drug therapy.^[10] Majority (93%) of the cases with osteonecrosis reported by the Food and Drug Administration (FDA) up to September 2008 were related to intravenous, and the rest to the oral bisphosphonate use with the indication of osteoporosis. The incidence of osteonecrosis of jaw(s) due to bisphosphonate use in various publications was

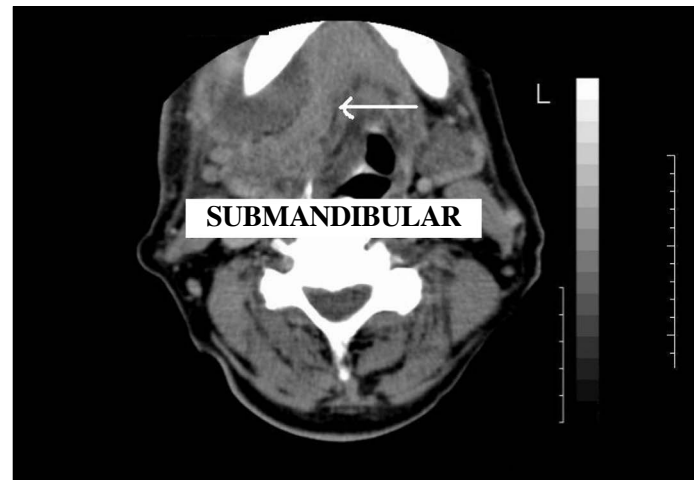


Figure 1. Submandibular abscess, maxillofacial computed tomography

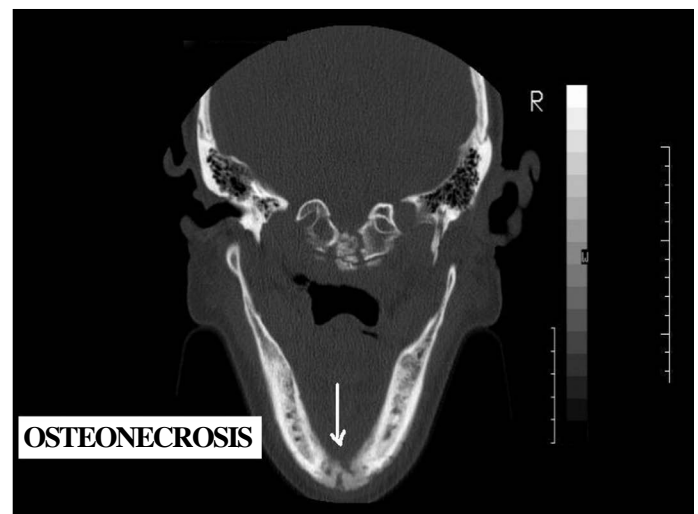


Figure 2. Mandibular sublingual fovea osteonecrosis in the mandible, maxillofacial computed tomography

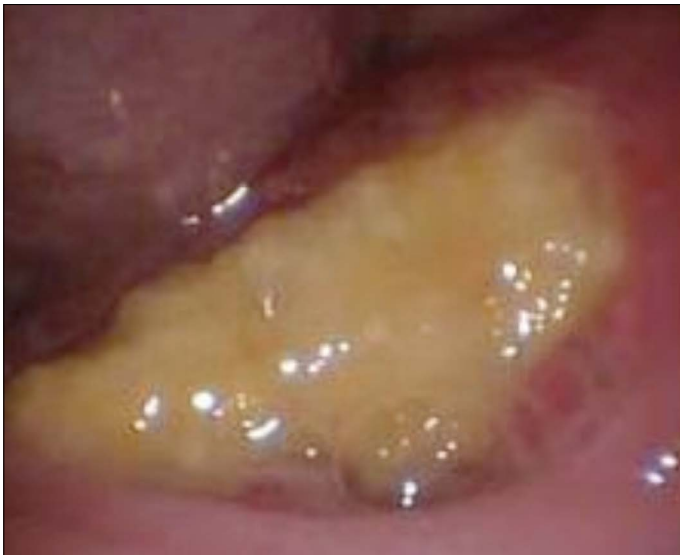

Figure 3. Mandibular focus of osteonecrosis in the mandible

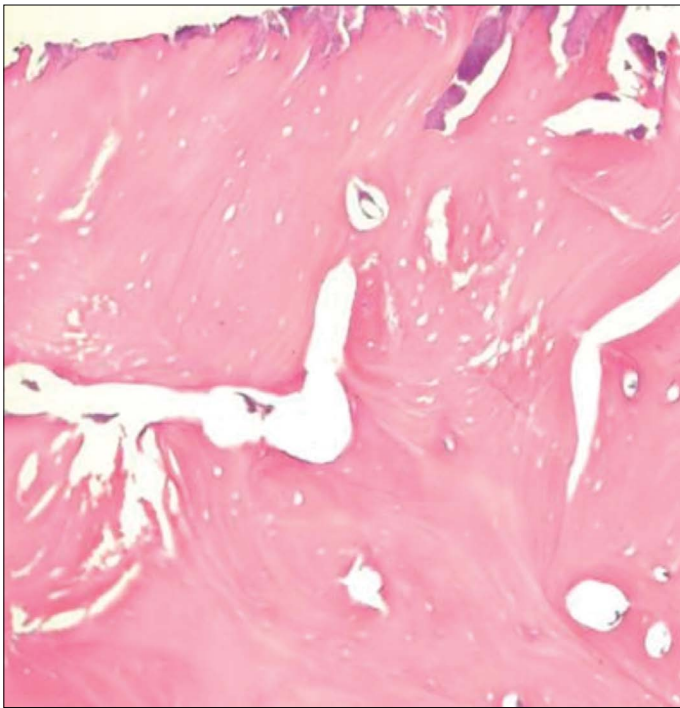

Figure 4. Osteonecrotic bone, histopathologic appearance

indicated to range between 1, and 21 percent. As suggested by many authors, in addition to clinically observed cases with osteonecrosis, occasionally radiological diagnosis is required.^[13,14] In a study, a group of patients who received IV bisphosphonate infusions for approximately 35 times during a median period of 39.3 (11-86 mos) months without development of osteonecrosis, and a group that received IV bisphosphonate infusions for 15 times during a median period of 39.3 months (11-86 mos), and developed osteonecrosis were compared. The authors reported

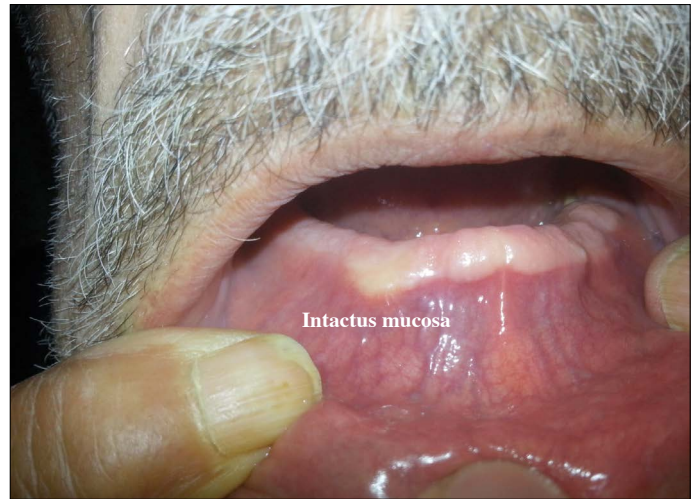

Figure 5. Healing of the mandibular mucosa after a period of follow-up

osteonecrosis development rates of more than 1%, and 4% of the patients who were under bisphosphonate treatment for 1, and 4 years, respectively, and claimed that these rates were higher in zoledronic acid users.^[15] Especially, in a series of 350 patients with osteonecrosis related to zoledronic acid, mandibular osteonecrosis was more prevalently observed.^[16] In a series of 252 patients who were using bisphosphonates since 1997, incidence rate of mandibular osteonecrosis was estimated as 6.7 percent.^[17] The incidence of osteonecrosis was reported as 8.6% in zolendronate, 7.3% in pamidronate users. While incidence of osteonecrosis was observedly risen to 21% in combined use of both drugs.^[12,18,19]

The most prevalent primary focus in breast, lung, and mandibular tumors was detected to be mandible, however mandible was the primary focus in only 9.6% of the cases with prostate cancer.^[18] As factors inducing mandibular, and maxillary osteonecrosis related to bisphosphonates, incessant movements of chewing, various microbiological agents, fragile mucosa 2 mm-thick which can be easily peeled away from the periosteum have been asserted.^[20]

A clear-cut opinion about the treatment of osteonecrosis with bisphosphonates is not available yet. The main targets of the treatment is relief of pain, control of the soft tissue infection, and prevention of the disease progression. American Association of Oral and Maxillofacial Surgeons (AAOOMS) recommends application of chlorhexidine gluconate, superficial curettage, and use of antibiotics based on the results of susceptibility tests for exposed bones.^[21] AAOOMS deems it suitable to start bisphosphonate therapy after completion of all dental therapies, including invasive interventions. In a series of 125 cases, penicilline or second-generation cephalosporins, chlorhexidine

gargles, periodic debridements, regular lavages of the wound site were applied.^[22] Still in another series, the authors stated that infection in adjacent tissues can be brought under control by using hyperbaric oxygen therapy which can eliminate anaerobic media, and induce neovascularization. They also emphasized angiogenic effect of hyperbaric oxygen in oncology patients.^[23-25] It has been reported that despite all these treatments, most of the time the patient did not respond to treatment, and laser biostimulation therapy could control especially development of soft tissue inflammation, and exert favourable effects on pain relief.^[24-26] In our patient additional surgery aiming at the healing of the osteonecrotic mucosal wound in the mandible was not required. Spontaneous mucosal healing was achieved with intraoral applications of antiseptic solutions, systemic oral cephalosporins, and local epithelization agents used for 3 months.

As a conclusion, in patients using biphosphonates with the indication of bone metastases, swelling, and pain in the chin, and face should suggest mandibular or maxillary bone necrosis! Biphosphonates have serious beneficial effects in patients with bone metastases. These benefits outweigh the risk of development of osteonecrosis Serious complications which might be related to bone metastases induced by biphosphonate use can be reduced. Sometimes, before initiating biphosphonate therapy in these patients, advice of the dentists is requested for the required preventive orthodontic measures. In patients under biphosphonate therapy despite assertions indicating that oral hygiene training will provide benefit in the reduction of risk of osteonecrosis, the possibility of development of mandibular and/or maxillary osteonecrosis related to biphosphonate use should be kept in mind albeit all prophylactic measures.^[11,11,27]

Informed Consent: Written informed consent was obtained from patient who participated in this case.

Peer-review: Externally peer-reviewed.

Author Contributions: Concept - A.Ş.; Design - A.Ş., S.A.; Supervision - A.Ş., S.A.; Funding - A.Ş.; Materials - A.Ş.; Data Collection and/or Processing - A.Ş.; Analysis and/or Interpretation - A.Ş., S.A.; Literature Review - A.Ş.; Writer - A.Ş., S.A.; Critical Review - A.Ş.

Acknowledgements: The authors would like to thank İdris Çıldır, MD from Ear & Nose & Throat department for his clinical follow-up of the patient during the submandibular abscess and supply for CT images, and again thank to Dt. Şener Taşdemir, for his evaluation of the pathology of the mandible.

Conflict of Interest: No conflict of interest was declared by the authors.

Financial Disclosure: The authors declared that this study has received no financial support.

References

1. Akarslan ZZ, Kahraman SA. Kemik metastazı yapmış prostat kanseri tedavisinde kullanılan bifosfonata bağlı olarak çene kemiklerinde gelişen osteonekroz: vaka raporu ve literatür derlemesi. Atatürk Üniv Dış Hek Fak Derg 2008;18:105-10.
2. Carlin BI, Andriole GL. The naturel history, skeletal complications and management of bone metastases in patients with prostate carcinoma. Cancer 2000;88:2989-94. [\[CrossRef\]](#)
3. Bock O, Felsenberg D. Bisphosphonates in the management of postmenopausal osteoporosis -optimizing efficacy in clinic practice. Clin interv Aging 2008;3:279-97.
4. Mashiba T, Mori S, Burr DB, Komatsubara S, Cao Y, Manabe T, et al. The effects of suppressed bone remodelling by bisphosphonates on microdamage accumulation and degree of mineralization in the cortical bone of grog rib. J Bone Miner Metab 2005;23:36-42. [\[CrossRef\]](#)
5. Sardoğan M. Postmenopozal osteoporoz tedavisi: bifosfonatlar. Akad Geriatri 2010;183-8.
6. Lin JH, Russell G, Gertz B. Pharmacokinetics of alendronate:an overview. Int J Clin Pract Suppl 1999;101:18-26.
7. Vincenzi B, Santini D, Dicuonzo G, Battistoni F, Gavasci M, La Cesa A, et al. Zolendronic acid-related antiangiogenesis modifications and survival in advanced breast cancer patients. J Interferon Cytokine Res 2005;25:144-51. [\[CrossRef\]](#)
8. Ott SM. Long-term safety biphosphonates. J Clin Endocrinol Metab 2005;90:1897-9. [\[CrossRef\]](#)
9. Oh HK, Chambers MS, Garden AS, Lim HJ, Park HJ. Osteoradionecrosis of the mandible: treatment outcomes and factors influencing the progress of osteoradionecrosis. J Oral Maxillofac Surg 2009;67:1378-86. [\[CrossRef\]](#)
10. Assaf AT, Smeets R, Riecke B, Weise E, Gröbe A. Incidence of bisphosphonate-related osteonecrosis of the jaw in consideration of primary diseases and concomitant therapies. Anticancer Res 2013;33:3917-24.
11. Marx RE, Sawatari Y, Fortin M, Broumand V. Biphosphanates -induced exposed bone (osteonecrosis/osteopetrosis) of the jaws:risk factors,recognition,prevention, and treatment. J Oral Maxillofac Surg 2005;63:1567-75. [\[CrossRef\]](#)
12. Levin L, Luder L. Jaw lesion and discomfort. JAMA 2013;310:2195-6. [\[CrossRef\]](#)
13. Assoline-Dayana Y, Chang C, Greenspn A, Shenfeld Y, Gershwith ME. Pathogenesis and natural history of osteonecrosis. Semin Arthritis Rheum 2002;32:94-124. [\[CrossRef\]](#)
14. Ruggiero S, Mehrotra B, Rosenberg TJ, Engroff SL. Osteonecrosis of th jaws associated with the use of bisphosphonates:a review of 63 cases. J Oral Maxillofac Surg 2004;62:527-34. [\[CrossRef\]](#)
15. Bamias A, Kastritis E, Bamia C, Moulopoulos LA, Melakopoulos I, Bozas G, et al. Osteonecrosis of the jaw in cancer after treatment bisphosphonates:incidence and risk factor. J Clin Oncol 2005;23:8580. [\[CrossRef\]](#)
16. Wood J, Bonjean K, Ruetz S, Bellahcene A, Devy L, Foidart JM, et al. Novel antiangiogenic effects of the bisphosphonate compound zoledronic acid. J Pharmacol Exp Ther 2002;302:1055-61. [\[CrossRef\]](#)

17. Bamias A, Kastiritis E, Bamia C, Mouloupoulos LA, Malekopoulos I, Bozas G, et al. Osteonecrosis of the jaw in Australia. *J Oral Maxillofac Surg* 2007;65:415-23.
18. Luckman SP, Coxon FP, Ebetino FH, Russell RG, Rogers MJ. Heterocycle-containing bisphosphonates cause apoptosis and inhibit bone resorption by preventing protein prenylation: evidence from structure-activity relationships in J774 macrophages. *J Bone Miner Res* 1998;13:1668-78. [\[CrossRef\]](#)
19. Marx RE. Oral & intravenous bisphosphonate-induced osteonecrosis of jaw. History, etiology, prevention, and treatment, Illinois: Quintessence Publishing Co. Inc. 2007.p.67-9.
20. Hellstein JW, Marek CL. Bisphosphonate osteochemonecrosis (bisphossy jaw: is this phossy jaw of the 21st century? *J Oral and Maxillo Fac Surg* 2005;63:682-9. [\[CrossRef\]](#)
21. American Association of Oral and Maxillofacial Surgeons Position Paper on Bisphosphonate-related osteonecrosis of the jaws. Advisory Task Force on Bisphosphonate-Related Osteonecrosis of the Jaws, American Association of Oral and Maxillofacial Surgeons. *J Oral Maxillofac Surg* 2007;65:369-76. [\[CrossRef\]](#)
22. Marx RE, Oral intravenous bisphosphonates-induced osteonecrosis of the jaws: History. Etiology, prevention and treatment. Hanover Park: Quintessence Books 2006.p.68-70.
23. Çevik P. Bisfosfonat kullanılan hastalarda oral cerrahi uygulamalarda karşılaşılabilecek sorunlar ve tedavisi. İ.Ü. Diş Hekimliği Fak. Öğrenci Bitirme Tezi. Danışman; Prof. Dr. Özen Doğan Onur 2009.
24. Pourzarandian A, Watanabe H, Aokia A. Histological and TEM examination of early stage of bone healing Er: YAG laser irradiation: *Photomed Laser Surg* 2004;22:342-50. [\[CrossRef\]](#)
25. Fleish H. Bisphosphonates: mechanism of action. *Endocr Rev* 1998;19:80-100. [\[CrossRef\]](#)
26. Ruggiero S, Gralow J, Marx RE, Hoff AO, Schubert MM, Hury JM, et al. Practical guidelines for the prevention, diagnosis and treatment of osteonecrosis of the jaw in patients with cancer. *J Clin Pract* 2006;2:7-14.
27. Hirshberg A, Shnaiderman-Shapiro A, Kaplan I, Berger R. Metastatic tumours to the oral cavity-pathogenesis and analysis of 673 cases. *Oral Oncol* 2008;44:743-52. [\[CrossRef\]](#)