

Carpet-like polypoid lesion in collagenous colitis with mucosal giant cells

Hugh James Freeman MD FRCPC FACP, Michael Nimmo MD FRCPath

CASE PRESENTATION AND IMAGES

A 78-year-old woman experienced intermittent watery diarrhea for more than one year. There was no previous antibiotic use, travel or other medical history. The physical examination was normal. Laboratory studies, including bloodwork and fecal cultures, were negative. Colonoscopy revealed sigmoid diverticulosis and a broad-based sessile, 'carpet-like' polypoid lesion at the hepatic flexure appearing to occupy approximately 40% to 50% of the colonic circumference; consequently, the lesion was biopsied (Figure 1) and ink-tattooed (for later laparoscopic removal). Biopsy sections (Figures 2 and 3) showed collagenous colitis with thickening of the basal collagen plate, an irregular lower border, entrapped nuclei, loss of overlying surface epithelium and increased inflammatory cells in the lamina propria. Subepithelial multinucleated giant cells were present (arrows). A trichrome stain highlighted the thickened basal collagen plate with entrapped nuclei (Figure 4). Over the next few weeks, her diarrhea completely resolved on a high-fibre diet regimen alone.

DISCUSSION

Collagenous colitis was first described more than three decades previously in middle-age to elderly women experiencing watery diarrhea (1,2). Since then, the epidemiology and clinical features of this entity

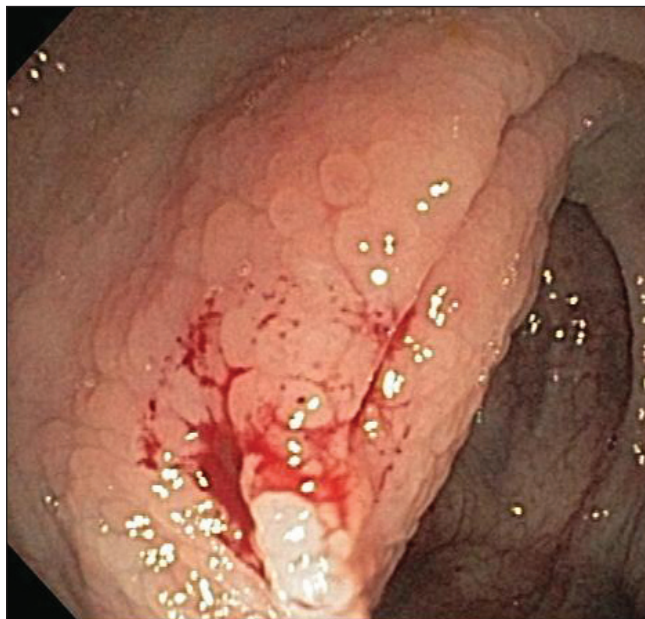

Figure 1) Sessile, 'carpet-like' polypoid lesion in the region of the hepatic flexure. The lesion was biopsied

have been detailed, the pathogenesis and histopathological features noted, and its outcome, complications and treatment described (3). Most often, the colonic mucosa is variably described by the endoscopist as normal or minimally altered; however, these changes are not specific. Some clinicians have reported submucosal dissection and colonic 'fracturing' after instrumentation or air insufflation during endoscopy, believed to be caused by a compromised colonic wall from collagen deposition (4,5), but it is not known whether these unusual endoscopic findings are specific for collagenous colitis per se. Pathological changes may be distributed uniformly throughout the colon, but in some cases, changes are patchy or discontinuous (6).

Detection of collagenous colitis with giant cells is rare, largely limited to the histopathological literature (7-10). In these reports, endoscopic findings were either normal or nonspecifically abnormal, with erythematous or 'edematous' mucosa. Biopsies of the sessile, carpet-like lesion showed the unanticipated pathological changes of an atypical form of collagenous colitis with giant cells. No adenomatous (dysplastic) epithelium was present. In retrospect, despite its extensive nature, the macroscopic lesion observed would not require colonoscopic or surgical removal. Indeed, even pharmacological treatment aimed at resolution of her symptoms was not necessary. The endoscopic findings noted here, however, add to previous endoscopic changes reported in collagenous colitis and extend the differential diagnosis of non-neoplastic sessile polypoid lesions.

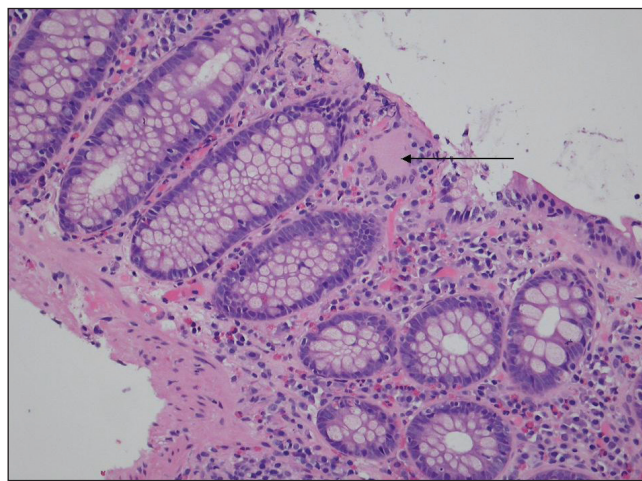


Figure 2) Collagenous colitis with giant cells (arrow) showing thickening of the basal collagen plate with an irregular lower border, entrapped nuclei and loss of the overlying surface epithelium. There are also increased inflammatory cells within the lamina propria (hematoxylin and eosin stain, low-power magnification)

Departments of Medicine (Gastroenterology) and Pathology, University of British Columbia, Vancouver, British Columbia

Correspondence: Dr Hugh James Freeman, University of British Columbia Hospital, 2211 Wesbrook Mall, Vancouver, British Columbia V6T 1W5.

Telephone 604-822-7216, fax 604-822-7236, e-mail hugfree@shaw.ca

Received for publication April 4, 2010. Accepted April 14, 2010

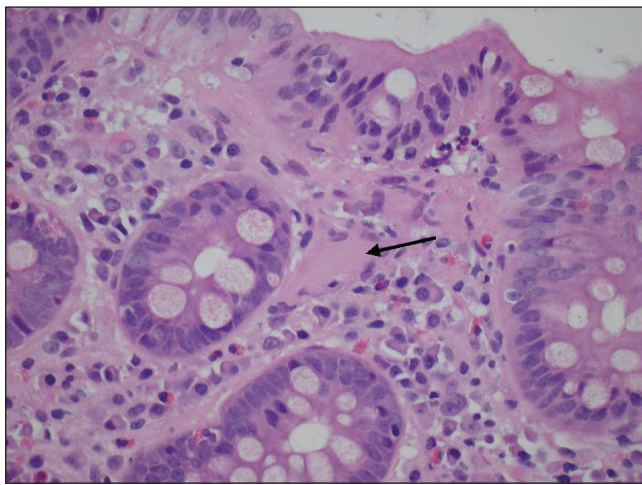


Figure 3) Collagenous colitis with giant cells. Higher power view demonstrating a giant cell (arrow) (hematoxylin and eosin stain)

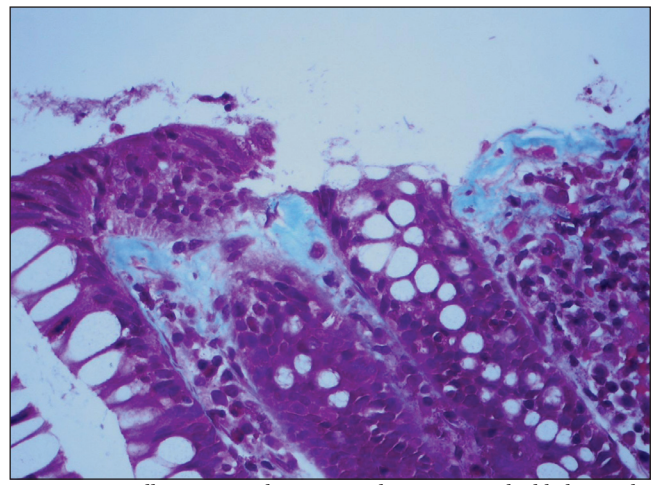


Figure 4) Collagenous colitis. A trichrome stain highlighting the thickened basal collagen plate with an irregular lower border and entrapped nuclei (medium power magnification)



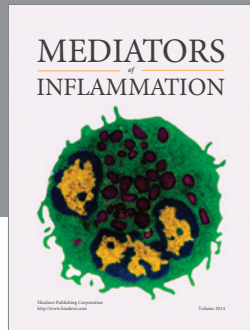
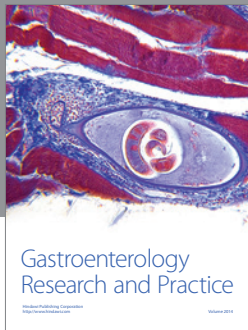
The precise cause of the histopathological finding detected in this particular patient remains elusive. Infectious causes were excluded and, clearly, the clinical findings were not consistent with an entity such as Crohn's disease. The location of these giant cells within the mucosa was primarily in the subepithelial region, believed by others (7) to reflect fusion

of subepithelial macrophages. It is intriguing that this is precisely the same subepithelial site as the collagen deposits in collagenous colitis. Further studies are needed to determine the possibly important role, if any, of these subepithelial multinucleated giant cells in the immunopathogenesis of the subepithelial collagen band deposits in collagenous colitis.

REFERENCES

1. Freeman HJ, Weinstein WM, Shnitka TK, Wensel RH, Sartor VE. Watery diarrhea syndrome associated with a lesion of the colonic basement membrane-lamina propria interface. *Ann Royal Coll Phys Surg Can* 1976;9:45.
2. Lindstrom CG. Collagenous colitis with watery diarrhea – a new entity? *Pathol Eur* 1976;11:87-9.
3. Freeman HJ. Collagenous mucosal inflammatory diseases of the gastrointestinal tract. *Gastroenterology* 2005;129:338-50.
4. Mitchell JD, Teague R, Bolton R, Lowes J. Submucosal “dissection” in collagenous colitis. *Gut* 2004;53:470.
5. Sherman A, Ackert J, Rajapaksa R, West AB, Oweity T. Fractured colon: An endoscopically distinctive lesion associated with colonic perforation following colonoscopy in patients with collagenous colitis. *J Clin Gastroenterol* 2004;38:341-5.
6. Offner FA, Jao RV, Lewin KJ, Havelec L, Weinstein WM. Collagenous colitis: A study of distribution of morphological abnormalities and their histological detection. *Hum Pathol* 1999;30:451-7.
7. Libbrecht L, Croes R, Ectors N, Staels F, Geboes K. Microscopic colitis with giant cells. *Histopathology* 2002;40:335-8.
8. Sandmeier D, Bouzourene H. Microscopic colitis with giant cells: A rare new histopathologic subtype? *Int J Surg Pathol* 2004;12:45-8.
9. Iwai H, Hisamatsu T, Iizuka H, et al. Microscopic colitis with granuloma which responded to steroid therapy. *Intern Med* 2007;46:1551-5.
10. Saurine TJ, Brewer JM, Eckstein RP. Microscopic colitis with granulomatous inflammation. *Histopathology* 2004;45:82-6.

The Canadian Journal of Gastroenterology will now consider a limited number of submissions for IMAGE OF THE MONTH. These will be based on endoscopic, histological, radiological and/or patient images, which must be anonymous with no identifying features visible. The patient must consent to publication and the consent must be submitted with the manuscript. All manuscripts should be practical and relevant to clinical practice, and not simply a case report of an esoteric condition. The text should be brief, structured as CASE PRESENTATION and DISCUSSION, and not more than 700 words in length. A maximum of three images can be submitted and the number of references should not exceed five. The submission may be edited by our editorial team.



Hindawi
Submit your manuscripts at
<http://www.hindawi.com>

